The Gulf Journal of Oncology

Indexed By PubMed and Medline Database

Issue 38, January 2022
ISSN No. 2078-2101

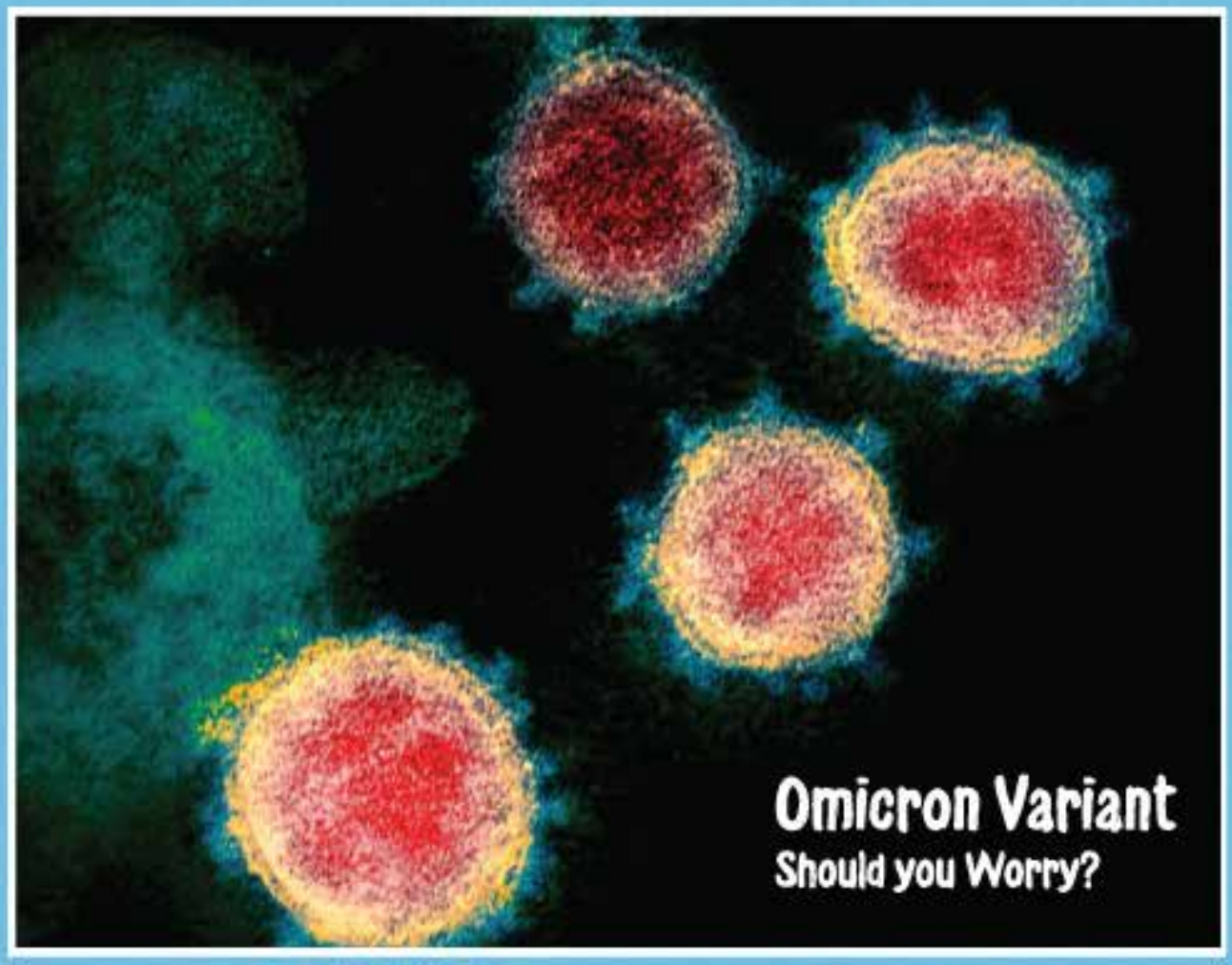

The Official Journal of the Gulf Federation For Cancer Control

Table of Contents

Original Articles

Image–Guided Brachytherapy a Comparison Between 192Ir and 60Co Sources in Carcinoma Uterine Cervix **07**
Mourougan Sinnatamby, Saravanan Kandasamy, Gunaseelan Karunanidhi, Vijayaprabhu Neelakandan, Seenisamy Ramapandian, Muniyappan Kannan, Elakiya Sampath

Immunohistochemical Analysis of Novel Biomarkers Cyclin D1, p53 And Ki67 in Endometrial Carcinoma: Clinicopathological Significance and Prognostic Value **15**
Manisha A. Atram, V B Shivkumar, Nitin M. Gangane

Serum Alkaline Phosphatase in Newly Diagnosed Genito–Urinary Cancers – Do We Need to Review the Guidelines? **24**
Rathee Ravish, Punatar Chirag B, Agrawal Gaurav, Nagaonkar Santoshi, Joshi Vinod S, Late Sagade Sharad N, Srinivas V

Post–Menopausal Status and Risk for Cervical Dysplasia **31**
Kenia Edwards, Mary Fatehi, Joshua Fogel

Impact of Screening Programs on Stage Migration in Breast Cancer **38**
Bassim Jaffar Al Bahrani, Itrat Mehdi, Taha Mohsin Al Lawati, Abdulaziz M Al Farsi, Najla A. Al Lawati, Hasina Al Harthi

Assessment of Voice Outcomes Post Chemo–Radiotherapy in Non–Laryngeal Head & Neck Cancers Using Electroglottography and Voice Symptom Scale (VoiSS) Questionnaire **47**
Nikhila Radhakrishna, B. K. Yamini, Amrut Sadashiv Kadam, N. Shivashankar, Chendil Vishwanathan, Rajesh Javarappa

Predictive and Prognostic Value of Tumor– Infiltrating Lymphocytes for Pathological Response to Neoadjuvant Chemotherapy in Triple Negative Breast Cancer **53**
Amrallah A. Mohammed, Fifi Mostafa Elsayed, Mohammed Algazar, Hayam E Rashed

A Prospective Study to Evaluate the Impact of Cancer Directed Treatment on Quality of Life in Head and Neck Cancer Patients **61**
Sujal Parkar, Abhishek Sharma, Mihir Shah

"CUIDARAS": A Nominal and Personalized Health Care Model. Effectiveness of a Massive Screening for Colorectal Cancer Detection at Community level **72**
Gustavo H. Marin, Hector Trebucq, Carlos Prego, Luis Mosquera, Gustavo Zanelli, Daniela Pena, Gustavo Sanchez, Marcela Mayet, Julieta Spina, Andrea Lalleé, Florencia Scigliano, Adrian Fernandez

Case Reports

Pseudotumor of the Infratemporal Fossa Complicated with Orbital Apex Syndromes **78**
Nik Mohd Syahrul Hafizzi Awang, Rosli Mohd Noor, Rosdi Ramli, Baharudin Abdullah

A Rare Occurrence: Triple 'True' Metachronous Endometrial, Nasal Cavity and Recto–Sigmoid Cancer **82**
Aashita, Vikas Yadav, Rajiv Sharma, Pragyat Thakur, Hemendra Mishra, Sanchit Jain

Uterine Perivascular Epithelioid Cell Tumor (PEComa) in A 56–year–Old Woman **86**
Ala Aljehani, Ahmed Abu–Zaid, Mohamed Ismail Albadawi, Osama Alomar, Abdulmohsen Alkushi

Intracranial Meningiomas Developed after Traditional Scalp Thermal Cautery Treatment in Childhood: Clinical Reports and Gene Expression Analysis **90**
Ashwag Alqurashi, Saleh Baeesa, Maher Kurdi, Deema Hussein, Hans–Juergen Schulten

Conference Highlights/Scientific Contributions

- **News Notes** **107**
- **Advertisements** **110**
- **Scientific events in the GCC and the Arab World for 2022** **111**

Original Article

Serum Alkaline Phosphatase in Newly Diagnosed Genito–Urinary Cancers – Do We Need to Review the Guidelines?

Rathee Ravish, Punatar Chirag B, Agrawal Gaurav, Nagaonkar Santoshi, Joshi Vinod S, Late Sagade Sharad N, Srinivas V

Department of Urology, P D Hinduja National Hospital and Medical Research Centre, Mumbai, India

Abstract

Objectives: To evaluate the role of alkaline phosphatase (ALP) as marker of bone metastases in patients of genito–urinary cancers compared to bone scan, and to correlate with NCCN guidelines.

Methods: This retro–prospective, observational study included all newly diagnosed patients of renal, bladder (muscle invasive) and prostate cancers who presented from July 2014 to March 2017. For diagnosis of bone metastases, ALP groups (raised/normal) were compared with bone scan (positive/negative). Sub–group analysis was done on patients with normal ALP levels and positive bone scan.

Results: 150 patients were included and stratified depending on bone scan findings. Hemoglobin values were significantly different between two groups in renal and prostate cancers (p=0.015 and 0.002 respectively). ALP values were significantly different between two groups in prostate cancers (p=0.0008), but not for others. Three out of seven patients with bone metastases for renal cancers (42.9%) and all three for bladder cancers had normal ALP values, no bone symptoms, and would have been missed. For prostate cancers, out of 23 who had bone metastases, ALP was normal in ten. All these ten had Gleason score of >8 and all except one had S. PSA >20ng/ml. All cases would have been detected irrespective of ALP values.

Conclusions: ALP has limited sensitivity but reasonable negative predictive value for bone metastases in genitourinary cancers. Current guidelines may miss significant number of cases with bone metastases for renal and bladder cancers. Current guidelines have good accuracy for prostate cancers, since PSA and Gleason score are independent predictors of bone metastases.

Keywords: Alkaline Phosphatase, Bone scan, Genito–urinary cancer

Introduction

There has been an increase in incidence of genitourinary malignancies in the past few years. In India in 2012, incidence of prostate cancer was 19,095, renal cancer was 9,658 and bladder cancer was 16,273[1].

Bone metastasis is a common feature of advanced genitourinary malignancies and prominent cause of morbidity and mortality. Clinical manifestations of bone metastases can include pain, pathologic fractures, spinal cord compression and hypercalcemia[2]. These complications diminish functional capabilities and have a huge impact on quality of life, and can lead to reduction in survival[3].

Treatment effectiveness and survival rates are highest when disease is still localized to the initial site. Once bone metastases occur, line of management changes from curative to probably palliative. Early detection of bone metastases helps in proper staging of cancer and thereby deciding the modality of treatment and avoiding unnecessary interventions. Also timely measures can be taken to avoid the above said complications.

Serum alkaline phosphatase (ALP) is one of the oldest available biochemical tools used for detection of bone metastases. It has stood the test of time and is used as an indicator of osteoblastic activity, as in bone metastases[4].

Corresponding Author: Punatar Chirag B, Department of Urology, P D Hinduja National Hospital and Medical Research Centre, Veer Savarkar Marg, Mahim westMumbai 400016, Maharashtra, India.
Phone +91–9820935675
Email: chirag_punatar@yahoo.in

Bone scan is a sensitive modality for detection of bone metastases[5]. There have been many debates, whether all patients with newly diagnosed genitourinary malignancies should undergo bone scanning or not, and whether ALP is sufficient to rule out bone metastases in low risk cases. Patients having lowest risk may have to undergo unnecessary testing, while those who are at higher risk may not be appropriately evaluated.

The guidelines for renal cancer and bladder cancer states that if ALP is normal, bone scan can be safely avoided in asymptomatic patients.

Objectives

In our study, we wanted to evaluate role of ALP as a marker of bone metastases in patients of renal, bladder (muscle invasive) and prostate cancers compared to bone scan in Indian population and correlate it with NCCN guidelines.

Materials And Methods

This retro–prospective, observational study was conducted at our institute and included all newly diagnosed patients of renal, bladder (muscle invasive) and prostate cancers who presented from July 2014 to March 2017. Those who had received any form of systemic therapy, and those not willing were excluded. The study was approved by Ethical committee and Institutional review board of the institute. Informed and written consent was taken from all participants.

Patients from July 2014 to July 2016 were taken as retrospective arm and those from August 2016 to March 2017 were included in prospective arm. Hospital medical records were reviewed for retrospective data while data from prospective arm was collected at the time of hospital visit.

Detailed history was taken and clinical examination done. Based upon symptoms at presentation, cases were divided into asymptomatic group, having localized symptoms and having metastatic symptoms. Laboratory investigations like complete blood count, renal function test, liver function test, PSA were carried out as necessary. Radiological Imaging like CT scan / MRI abdomen and pelvis for local staging and bone scan for bone metastases was done. Tissue biopsy (TURBT and Prostate Biopsy) was taken wherever required.

For diagnosis of bone metastases, ALP groups (raised/normal) were tested to bone scan (positive/negative) using sensitivity, specificity, positive predictive value (PPV) and negative predictive value (NPV) and area under curve (AUC). A sub group analysis was done on patients with normal ALP levels and positive bone scan. ALP value between 40–120 IU/l was considered normal and above 120 IU/l was considered raised.

Quantitative data (age, haemoglobin, ALP, PSA) were represented as mean ± standard deviation. Qualitative data (gender, presentation, bone scan, staging, Gleason score) were represented as frequency and percentages.

Data recording was done in MS Excel. Data analysis was done using MedCalc software (v.17). All tests were two–tailed, and the results were considered significant at $p \leq 0.05$.

Results

Total 156 patients were newly diagnosed with genito–urinary cancers during the study period. Six patients were excluded as per exclusion criteria. Four patients did not give consent, and two had received prior systemic therapy. One hundred and fifty patients were included. Sub–group analysis was done separately for renal, bladder and prostate cancers.

The demographic details and presenting symptoms are as mentioned in Table 1.

All the patients underwent bone scan to diagnose whether bone metastases were present or not. Within all the sub–groups, patients were further stratified depending on whether bone metastases were present or not. p values were calculated for each parameter separately (i.e. hemoglobin, ALP values, age, PSA values, Gleason score) to determine whether statistically significant or not. The results are shown in Table 2. Hemoglobin values

	Renal cancers	Bladder cancers	Prostate cancers
Number of patients	n = 60	n = 28	n = 62
Mean age (± SD) (years)	58.6 ± 12.36	70 ± 9.35	70.19 ± 7.99
Age range (years)	28 – 84	45 – 87	41 – 88
Gender distribution (M/F)	37 / 23	24 / 4	62 / 0
Presentation			
Asymptomatic	35 (58.3%)	0 (00.0%)	11 (17.7%)
Local symptoms	21(35.0%)	28 (100%)@	41 (66.2)
Metastatic symptoms	04 (06.7%)	0 (00.0%)	10 (16.1%)

@ 6 patients had upgrading on repeat histopathology

Table 1. Demographic details of patients

Parameters	Renal cancers (n = 60)			Bladder cancers (n = 28)			Prostate cancers (n = 62)		
	Bone scan +	Bone scan –	p value	Bone scan +	Bone scan –	p value	Bone scan +	Bone scan –	p value
Mean Age (± SD)	54.57 ± 16.65	59.13 ± 11.78	0.363	70 ± 9.2	70 ± 9.6	1.000	69 ± 8	71 ± 8	0.366
Hemoglobin	9.8 ± 2.9	12.3 ± 2.4	**0.015**	10.10 ± 4.1	12.28 ± 2.2	0.144	11.9 ± 1.8	13.3 ± 1.6	**0.002**
ALP	84.1 ± 56.2	82.6 ± 38.2	0.561	78.33 ± 23.11	75.67 ± 32.67	0.566	370 ± 461.2	72.3 ± 23.6	**0.0008**

Table 2. Correlation of various parameters with bone scan

Parameter	Renal cancers (n = 60)			Bladder cancers (n = 28)			Prostate cancers (n = 62)		
TNM stage	Bone scan +	Bone scan –	Total	Bone scan +	Bone scan –	Total	Bone scan +	Bone scan –	Total
T1	03	37	40	00	00	00	03	18	21
T2	02	08	10	02	19	21	10	19	29
T3	02	06	08	00	03	03	10	01	11
T4	00	02	02	00	01	01	00	00	00
N1	00	00	00	01	02	03	00	01	01
Total	07	53	60	03	25	28	23	39	62

Table 3. Correlation of TNM staging with bone scan

ALP	Renal cancers (n = 60)			Bladder cancers (n = 28)			Prostate cancers (n = 62)		
	Bone scan +	Bone scan –	Total	Bone scan +	Bone scan –	Total	Bone scan +	Bone scan –	Total
Normal	05	43	48	03	24	27	10	38	48
Raised	02	10	12	00	01	01	13	01	14
Total	07	53	60	03	25	28	23	39	62

Table 4. Correlation of ALP with bone scan

were significantly low in those patients whose bone scan was positive, compared to those whose bone scan was negative in renal and prostate cancers, but not bladder cancers. ALP values were significantly high in patients with positive bone scan, compared to those with negative bone scan in cases of prostate cancers, but not for renal and bladder cancers.

The correlation of TNM stage and bone scan findings is shown in Table 3. In general, the incidence of bone metastases goes on increasing as the T and N stage increases. There were no N1 renal cancers, T1 bladder cancers (non invasive bladder cancers were not included), and T4 prostate cancers in our study.

The correlation of ALP and bone scan findings is shown in Table 4.

For renal cancers, of the cases who had bone scan positive ALP was raised in two (28.6%) and normal in five (71.5%) cases. Out of these five cases who had bone scan positive and normal ALP levels, three cases had no bone pain at the time of presentation. Thus following current guidelines three out of seven (42.9%) cases would have been missed if bone scan is done only when either ALP is raised or bone pain is present. Out of these three cases, one case belonged to stage T1b, one to stage T2a and third to stage T3a. Out of these three cases one had lung metastases. Hence two cases would have been incorrectly staged.

For bladder cancers, three out of 28 (10.7%) cases had bone scan positive in our study. ALP was normal in all these cases and none had bone pain. Two cases belonged to stage T2 and one case had lymph node

PSA / Gleason score	Bone scan +	Bone scan –	P value / total	Percentage of bone scan positivity
Mean PSA (ng/ml)	286.10 ± 356.61	32.04 ± 52.99	**0.00003**	
PSA Range (ng/ml)				
< 10	01	10	11	09.10%
10 – 20	02	16	18	11.10%
> 20.1	20	13	33	60.60%
Total	23	39	62	37.09%
Gleason score				
3+3	00	11	11	00.00%
3+4	01	12	13	07.69%
4+3	02	08	10	20.00%
4+4	12	06	18	66.67%
4+5	05	01	06	83.33%
5+4	01	00	01	100.00%
5+5	01	01	02	50.00%
3+5	01	00	01	100%
Total	23	39	62	37.09%

Table 5. Correlation of PSA and Gleason score with bone scan in prostate cancer patients

PSA sub–group	Our series (n = 62)	Tanaka N et al[16] (n = 857)	Wymenga L.F.A et al[17] (n = 363)
< 10	01/11 (09.10%)	02/466 (00.42%)	14/89 (15.73%)
10 – 20	02/18 (11.11%)	01/187 (00.53%)	05/56 (08.92%)
> 20.1	20/33 (60.60%)	38/204 (18.62%)	92/217 (42.39%)
TNM Stage	**Our series (n = 62)**	**Tanaka N et al[16] (n = 857)**	**Wymenga L.F.A et al[17] (n = 351)**
T1	03/21 (14.28%)	01/375 (00.30%)	04/55 (07.27%)
T2	10/29 (34.48%)	08/300 (02.70%)	09/88 (10.22%)
T3	10/11 (90.90%)	26/162 (16.00%)	75/185 (40.54%)
T4	00/00 (00.00%)	05/20 (25.00%)	17/23 (73.91%)
Gleason score	**Our series (n = 62)**	**Tanaka N et al[16] (n = 857)**	**Briganti A et al[18] (n = 853)**
6	00/11 (00.00%)	00/304 (00.00%)	03/482 (00.62%)
7	03/23 (13.04%)	10/373 (02.68%)	03/282 (02.12%)
8 – 10	20/28 (71.40%)	30/180 (16.67%)	15/89 (16.85%)

Table 7. Comparison of PSA, Gleason score, and stage with bone scan in various series

ALP	Renal cancers (n = 60)	Bladder cancers (n = 28)	Prostate cancers (n = 62)
Sensitivity	28.60%	00.00%	56.45%
Specificity	81.10%	96.00%	97.40%
NPV	89.60%	88.89%	79.20%
PPV	16.70%	00.00%	92.80%
AUC	0.55	0.48	0.77

Table 6. Sensitivity, specificity, NPV, PPV and AUC for ALP

enlargement on imaging. One case had raised ALP but bone scan was negative in this case. All (three out of three) cases would have been missed in our study if bone scan was done only in cases who had bone pain or raised ALP.

For prostate cancers, out of 23 cases who had bone metastases ALP was raised in 13 and normal in ten. It was raised in one case in which bone metastasis was absent. Out of these ten cases where bone metastases were present but ALP was normal, one had bone pain at the time of presentation, remaining nine had no bone symptoms. All these ten cases had Gleason score of >8 and all except one had S. PSA >20 ng/ml. So all cases would have been detected following current guidelines irrespective of ALP values.

Additionally for prostate cancer patients, correlation was done with PSA levels and Gleason score. The findings are tabulated in Table 5.

The sensitivity, specificity, NPV, PPV, and AUC for ALP are as shown in Table 6.

Discussion

There have been debates whether bone scan is necessary in all cases of newly diagnosed genito–urinary cancers or ALP is sufficient in absence of symptoms and/or high risk factors. Ours was a retro prospective observational study carried out from July 2014 to March 2017. We hereby briefly review our findings in comparison to already published studies.

Renal cancers

For renal cancers, mean age in our study was 58.6±12.36 years, which is similar to earlier studies. In a retrospective study of 140 subjects done by Klaus Jung et al[6] median age was 59 years with a range of 35 to 86 years. Male to female ratio in our study was 1.6:1 which is similar to earlier studies varying between 3:2 to 3:1[6,7,8]. In our study 58.3% of cases were incidentally diagnosed while 35% had local symptoms. In their retrospective study of 1092 cases, Luciani et al[9] found that 45.8% of all cases were incidentally diagnosed and this share of incidentally detected masses is on rise. Jayson et al[10] in their study found that 61% of total cases were incidentally diagnosed. Thus emphasizing that incidence of asymptomatic masses detected on routine investigations is on the rise.

In our study, in cases without bone metastases mean haemoglobin was 12.3±2.4 gm/dl and in those with bone metastases it was 9.8±2.9 gm/dl (p=0.015). Lower haemoglobin in such cases could be because of para–neoplastic syndromes or advanced disease stage.

Majority of the cases in our study were early stage. None of stage T1a, 10% of stage T1b, 20% of stage T2 and 37.5% of stage T3 cases had bone metastases. None in stage T4 had bone metastases, this could be because of small number of cases in that group. In a retrospective study of 205 cases conducted by Koga S et al[11], of the cases in stage T1a, T1b, T2, T3 and T4, 5%, 22%, 27%, 51% and 88% had bone metastases respectively at the time of diagnosis, highlighting the fact that in small renal tumors chances of metastases is less and it goes on increasing as stage increases. However, stage of the disease did not act as an indicator of bone metastases in our study.

In our study mean ALP in cases without bone metastases was 82.6±38.2 IU/l and was 84.1±56.2 IU/l in cases with bone metastases (p=0.561). Klaus Jung et al[6] in their retrospective study found that mean ALP in cases without bone metastases was 82 IU/l and with bone metastases was 122 IU/l. In a retrospective study of 205 cases by Koga S et al[11] 65% of cases with bone metastases had normal ALP and 35% had raised ALP levels. Seaman E et al[12] in their retrospective analysis of 90 cases found that ALP was normal in 11 (39%) out of 28 cases who had bone metastases, out of these 11, eight had bone pain at the time of presentation.

Bladder cancers

For bladder cancers, in our study mean age was 70±9.35 years. In a retrospective analysis of 179 cases by Taher Azza N et al[13] mean age was 57.4±8.9 years. This difference could probably be because of lesser incidence of smoking in our population which is an important risk factor for bladder cancer. Male to female ratio in our study was 6.9:1 which is different from published data in which it is around 2.6 to 4:1[7,14]. This difference could be because of less prevalent smoking in females in our country. In our study 78.6% cases had local symptoms whereas 21.4% cases had upgrading of disease from non–muscle invasive to muscle invasive disease. None was detected on routine evaluation. In our study 75% cases belonged to stage T2, 10.7% to stage T3, 3.6% to stage T4 and 10.7% cases had lymph node enlargement on imaging studies. In their study Braendengen et al[14] found that 34.1% cases belonged to stage T2, 63.7% to stage T3 and 2.2% cases belonged to stage T4a.

Mean ALP in cases without bone metastases was 75.67±32.67 IU/l and in those with bone metastases was 78.33±23.11 IU/l. p value was 0.56 emphasizing that difference in ALP values in two groups is not statistically significant. Three out of 28 (10.7%) cases had bone scan positive in our study while ALP was normal in all of these cases and none had bone pain at the time of presentation. One case had raised ALP but bone scan was negative. In their study Abbosh P et al[15] evaluated 176 cases, 38 of whom had bone scan positive out of whom 18 had raised ALP and 20 cases had normal ALP. Further 20 cases had raised ALP in whom bone scan was negative. All (three out of three) cases in our study would have been missed if bone scan was done only in cases who had bone pain or raised ALP.

Prostate cancers

For prostate cancers, in our study mean age of cases was 70.19±7.99 years. Tanaka N et al[16] in their study found that mean age of all cases was 70 years.

Mean haemoglobin of cases with bone metastases in our study was 11.9±1.8 gm/dl and in those without bone metastases was 13.3±1.6 gm/dl (p value 0.002). This difference could be because of bone metastases destroying bone marrow thus leading to anaemia.

In cases without bone metastases mean PSA was 32.04±52.99 ng/ml whereas in cases with bone metastases mean was 286.10±356.61 ng/ml (p value

<0.0001). Tanaka N et al[16] in their study found that mean PSA in cases without bone metastases was 24.2±9.1 ng/ml and with metastases was 630.1±241.9 ng/ml (p value 0.001).

The number and percentage of cases having bone metastases in different PSA sub–groups, Gleason score and TNM stage in various series is as shown in Table 7. Percentage of cases having bone metastases in each PSA group and Gleason sub group is more in our studies than in published studies[16,17], this could be because of aggressive disease in our population, and also because of small sample size which may not represent general population.

In our study, out of 23 cases who had bone metastases ALP was raised in 13 cases and was normal in ten cases while it was raised in one case in which bone metastases was absent. Sensitivity, specificity, NPV, PPV and AUC of ALP was 56.4%, 97.4%, 79.2%, 92.8% and 0.77 respectively. Out of these ten cases where bone metastases were present but ALP was normal only one had bone pain at the time of presentation. All of these ten cases had Gleason score of >8 and all except one had S. PSA >20 ng/ml. So all cases would have been detected following current guidelines[19] irrespective of ALP values.

In study carried out by Ozgur B C et al[20] out of 220 cases, 44 had bone metastases and S. ALP was raised in 13 of such cases, while it was raised in 50 other cases in whom bone metastases was absent. Sensitivity, specificity, NPV and PPV was 38.2%, 71.6%, 85.7% and 20.6% respectively. In their study Ozu C et al[21] calculated sensitivity, specificity, NPV and PPV for ALP 69.1%, 89.5%,87.2% and 65.5% respectively.

Our study did have some limitations. This was a single centre study. Sample size was relatively small, hence generalization of our findings is limited. Although bone scan is a highly sensitive imaging modality to detect to bone metastases, we could not confirm histology of bone metastases by bone biopsy.

Conclusions

Based upon our study finding we conclude that ALP has limited sensitivity but reasonable NPV for bone metastases in genitourinary cancers. For renal and bladder cancers, our study shows that a significant number of cases with bone metastases may be missed if we follow current guidelines. However, for prostate cancers, since PSA, Gleason score and clinical stage act as independent predictors of bone metastases, current guidelines have good accuracy.

Acknowledgements

The authors would like to acknowledge The National Health and Education Society. The study was done at P D Hinduja National Hospital and Medical Research Centre, Mumbai.

References

1. GLOBOCON 2012, http://globocan.iarc.fr/Pages/summary_table_site_sel.aspx
2. Phillip S, Andrew A, Karim F, Stephen F, et al. New and emerging therapies for bone metastases in genitourinary cancers. Eur Urol Feb 2013;63(2):309–320.
3. Saad F, Lipton A, Cook R, et al. Pathological fractures correlate with reduced survival in patients with malignant bone disease. Cancer 2007;110:1860–67.
4. Bishop MC, Hardy JG, Taylor MC, Wastie MI, Lemberger RJ. Bone imaging and serum phosphatase in prostatic carcinoma. Br J Urol 1985;57:317–24.
5. Gerber G, Chodak GW. Assessment of value of routine bone scans in patients with newly diagnosed prostate cancer. Urology 1991;37:418–22.
6. Jung K, Lein M, Ringsdorf M, Roigas J, et al. Diagnostic and Prognostic Validity of Serum Bone Turnover Markers in Metastatic Renal Cell Carcinoma. The Journal of Urology October 2006; 176:1326 –31.
7. Siegel R, Naishadham D, Jemal A. Cancer Statistics, 2013. CA Cancer J Clin.2013; 63:11–30.
8. Ng CS, Wood CG, Silverman PM, et al. Renal cell carcinoma: diagnosis, staging and surveillance. AJR 2008; 191:1220–1232.
9. Luciani LG, Cestari R, Tallarigo C. Incidental renal cell carcinoma: age and stage characterization and clinical implications – study of 1092 patients (1982–1997). Urology 2000;56:58–62.
10. Jayson M, Sanders H. Increased incidence of serendipitously discovered renal cell carcinoma. Urology 1998; 51:203–205.
11. Koga S, Tsuda S, Nishikido M, et al. The diagnostic value of bone scan in patients with Renal Cell carcinoma. The Journal of Urology, December 2001;166:2126–28.
12. Seaman E, Goluboff ET, Ross S, Sawczuk IS. Association of radionuclide bone scan and serum alkaline phosphatase in patients with metastatic renal cell carcinoma. Urology Nov 1996; 48(5):692–5.
13. Taher Azza N, Kotb MH. Bone metastasis in muscle invasive bladder cancer. Journal of Egyptian Nat. Cancer Inst. September 2006; 18(3):203–208.

14. Braendengen M, Winderen M, Fossa SD. Clinical significance of routine pre cystectomy bone scans in patients with muscle invasive bladder cancer. British Journal of Urology1996;77:36–40.

15. Abbosh P, St Louis MO, Kibel A, et al. Evaluation of alkaline phosphatase as a marker for bone metastasis in patients with Muscle Invasive Bladder Cancer. The Journal of Urology May2013; 189:No.4S, Supplemente770.

16. Tanaka N, Fujimoto K, Shinkai T, et al. Bone scan can be spared in asymptomatic prostate cancer patients with PSA <20 ng/ml and Gleason score of <6 at the initial stage of diagnosis. Jpn J Clin Oncol2011;41(10)1209–13.

17. Wymenga LFA, Boomsma JHB, Groenier K, et al. Routine bone scans in patients with prostate cancer related to serum prostate specific antigen and alkaline phosphatase. BJU International 2001;88:226–30.

18. Briganti A, Passoni N, Ferrari M, et al. When to perform bone scan in patients with newly diagnosed prostate cancer: External validation of the currently available guidelines and proposal of a novel risk stratification tool. European Urology 2010;57:551–58.

19. NCCN. Clinical Practice Guidelines in Oncology prostate cancer version 3. 2016. https://www.nccn.org

20. zgür B C, Gültekin S, Ekici M, Yilmazer D, Alper M. A narrowing range of bone scan in newly diagnosed prostate cancer patients: A retrospective comparative study. Urology Annals, 2015 Apr –Jun; 7(2):193–198.

21. Ozu C, Nakashima J, Horiguchi Y, Oya M, Ohigashi T, Murai M. Prediction of bone metastases by combination of tartarate–resistant acid phosphatase, alkaline phosphatase and prostate specific antigen in patients with prostate cancer. International Journal of Urology 2008;419–422.