The Gulf Journal of Oncology

Indexed By PubMed and Medline Database

Issue 38, January 2022
ISSN No. 2078-2101

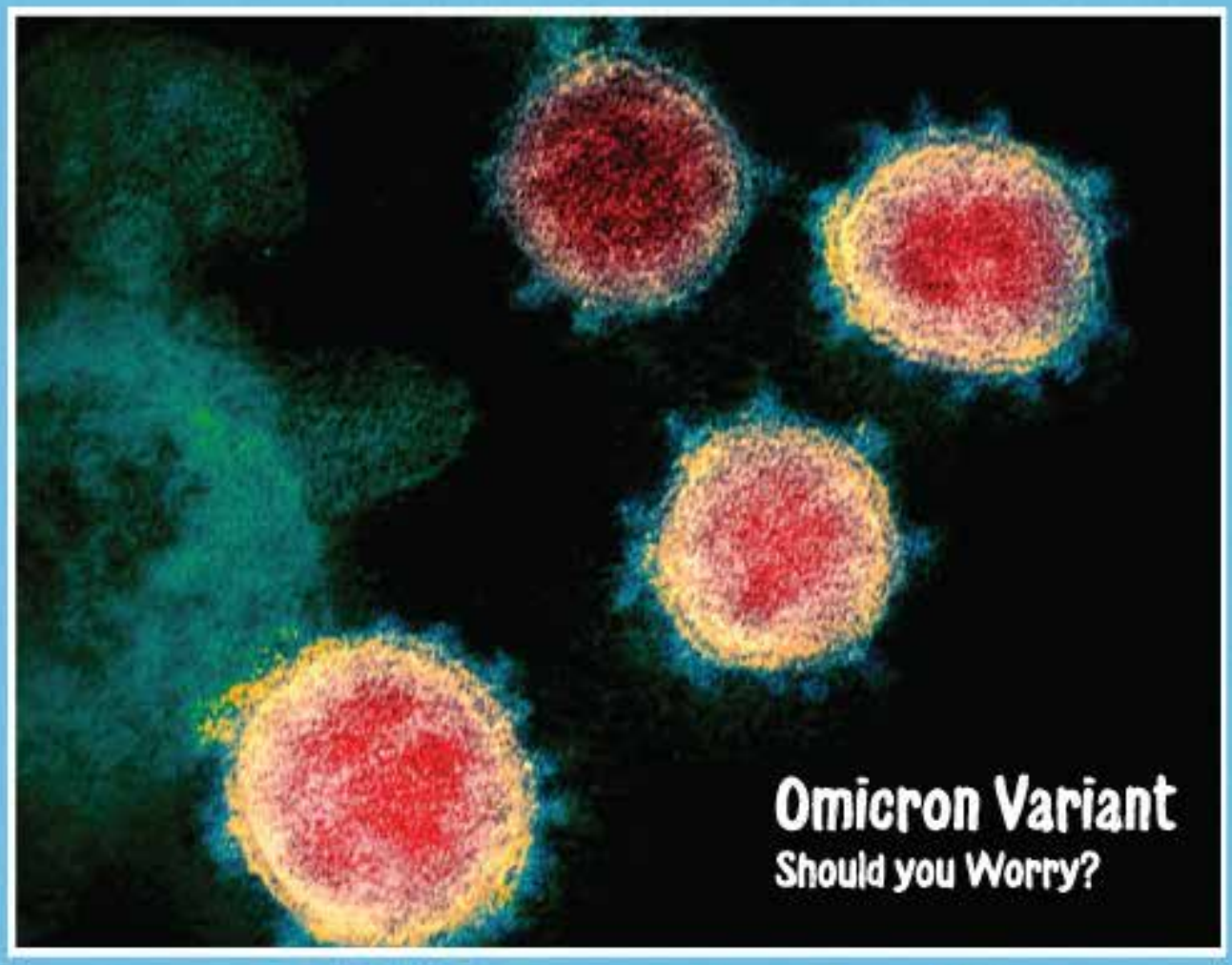

The Official Journal of the Gulf Federation For Cancer Control

Table of Contents

Original Articles

Image–Guided Brachytherapy a Comparison Between 192Ir and 60Co Sources in Carcinoma Uterine Cervix **07**
Mourougan Sinnatamby, Saravanan Kandasamy, Gunaseelan Karunanidhi, Vijayaprabhu Neelakandan, Seenisamy Ramapandian, Muniyappan Kannan, Elakiya Sampath

Immunohistochemical Analysis of Novel Biomarkers Cyclin D1, p53 And Ki67 in Endometrial Carcinoma: Clinicopathological Significance and Prognostic Value **15**
Manisha A. Atram, V B Shivkumar, Nitin M. Gangane

Serum Alkaline Phosphatase in Newly Diagnosed Genito–Urinary Cancers – Do We Need to Review the Guidelines? **24**
Rathee Ravish, Punatar Chirag B, Agrawal Gaurav, Nagaonkar Santoshi, Joshi Vinod S, Late Sagade Sharad N, Srinivas V

Post–Menopausal Status and Risk for Cervical Dysplasia **31**
Kenia Edwards, Mary Fatehi, Joshua Fogel

Impact of Screening Programs on Stage Migration in Breast Cancer **38**
Bassim Jaffar Al Bahrani, Itrat Mehdi, Taha Mohsin Al Lawati, Abdulaziz M Al Farsi, Najla A. Al Lawati, Hasina Al Harthi

Assessment of Voice Outcomes Post Chemo–Radiotherapy in Non–Laryngeal Head & Neck Cancers Using Electroglottography and Voice Symptom Scale (VoiSS) Questionnaire **47**
Nikhila Radhakrishna, B. K. Yamini, Amrut Sadashiv Kadam, N. Shivashankar, Chendil Vishwanathan, Rajesh Javarappa

Predictive and Prognostic Value of Tumor– Infiltrating Lymphocytes for Pathological Response to Neoadjuvant Chemotherapy in Triple Negative Breast Cancer **53**
Amrallah A. Mohammed, Fifi Mostafa Elsayed, Mohammed Algazar, Hayam E Rashed

A Prospective Study to Evaluate the Impact of Cancer Directed Treatment on Quality of Life in Head and Neck Cancer Patients **61**
Sujal Parkar, Abhishek Sharma, Mihir Shah

"CUIDARAS": A Nominal and Personalized Health Care Model. Effectiveness of a Massive Screening for Colorectal Cancer Detection at Community level **72**
Gustavo H. Marin, Hector Trebucq, Carlos Prego, Luis Mosquera, Gustavo Zanelli, Daniela Pena, Gustavo Sanchez, Marcela Mayet, Julieta Spina, Andrea Lalleé, Florencia Scigliano, Adrian Fernandez

Case Reports

Pseudotumor of the Infratemporal Fossa Complicated with Orbital Apex Syndromes **78**
Nik Mohd Syahrul Hafizzi Awang, Rosli Mohd Noor, Rosdi Ramli, Baharudin Abdullah

A Rare Occurrence: Triple 'True' Metachronous Endometrial, Nasal Cavity and Recto–Sigmoid Cancer **82**
Aashita, Vikas Yadav, Rajiv Sharma, Pragyat Thakur, Hemendra Mishra, Sanchit Jain

Uterine Perivascular Epithelioid Cell Tumor (PEComa) in A 56–year–Old Woman **86**
Ala Aljehani, Ahmed Abu–Zaid, Mohamed Ismail Albadawi, Osama Alomar, Abdulmohsen Alkushi

Intracranial Meningiomas Developed after Traditional Scalp Thermal Cautery Treatment in Childhood: Clinical Reports and Gene Expression Analysis **90**
Ashwag Alqurashi, Saleh Baeesa, Maher Kurdi, Deema Hussein, Hans–Juergen Schulten

Conference Highlights/Scientific Contributions

- **News Notes** **107**
- **Advertisements** **110**
- **Scientific events in the GCC and the Arab World for 2022** **111**

Case Report

Pseudotumor of the Infratemporal Fossa Complicated with Orbital Apex Syndromes

Nik Mohd Syahrul Hafizzi Awang[1], Rosli Mohd Noor[1], Rosdi Ramli[1], Baharudin Abdullah[2]

[1] Department of ORL, Hospital Raja Perempuan Zainab (II), Kota Bharu, Kelantan, Malaysia
[2] Department of Otorhinolaryngology–Head and Neck Surgery, School of Medical Sciences, Universiti Sains Malaysia, 16150 Kubang Kerian, Kelantan, Malaysia.

Abstract

Background: The infratemporal fossa poses a great challenge to surgeons due to its complex anatomy and communications to many surrounding areas. The disorders that arise from this area can be infections and neoplasms. They can cause varieties of complications due to the extension of the pathologies and compression effect to the other adjacent structures. Inflammatory pseudotumor of the infratemporal fossa is one of the rare disorders of the head and neck.

Case Presentation: We report a patient with a pseudotumor of infratemporal fossa that extends to the orbital area and cavernous sinus, causing orbital apex syndromes. The diagnostic imaging, different surgical approaches of the biopsy and methods of treatment of this case are discussed.

Discussion and Conclusion: Radiological imaging and immunohistopathology are essential in establishing the diagnosis and determine the complications. The surgeons must well understand the characteristics and the impact of the disorders on the adjacent structure and give prompt decision to provide definitive treatments.

Keywords: infratemporal fossa, inflammatory pseudotumor, immunohistopathology, orbital apex syndromes, cavernous sinus

Introduction

Inflammatory pseudotumor of the infratemporal fossa is a rare head and neck diseases, although it can occur throughout the body(1). Clinically this disease causes neoplastic proliferation, but histopathologically it is a benign disease involving nonspecific chronic inflammation(2). Infratemporal space is one of the three spaces within the masseteric space; the other two are pterygomaxillary space and submasseteric space(3). Due to the nature of the infratemporal space which resides near the orbit and other important structure, any lesion that arises from the infratemporal space may extend to adjacent structure and cause multiple complications. We are presenting a case of inflammatory pseudotumor of infratemporal fossa that extends to the orbital area and cavernous sinus, causing orbital apex syndromes. In this case report, we will emphasize the essential of the radiological imaging in the diagnosis of this disease, different approaches of the biopsy for infratemporal fossa mass and methods of treatment.

Case report

A case of 47 years old with underlying hypertension was referred to Otorhinolaryngology (ORL) department from Ophthalmology team. She presented with painful ophthalmoplegia of the right eye and ptosis for past two weeks associated with right facial paresthesia and headache. She also experienced difficulty in mouth opening for the past two months, which gradually worsening in nature. A neurological examination showed complete paralysis of III, IV and VI cranial nerve, reduce vision on the right eye and hypoesthesia in the maxillary division of the right trigeminal nerve (V2). No palpable cervical lymph nodes. Endoscopic nasopharynx examination revealed normal findings. Computed Tomographic (CT) scan demonstrated the presence of heterogeneous enhancing soft tissue mass, epicentre at right infratemporal region extending into the right maxillary sinus, pterygopalatine fossa, right orbit and right cavernous sinus measuring approximately 3.6cmx4.4cmx4.8cm (Fig. 1).

Corresponding author: Prof Dr Baharudin Abdullah, Department of Otorhinolaryngology–Head and Neck Surgery, School of Medical Sciences, Universiti Sains Malaysia, 16150 Kubang Kerian, Kelantan, Malaysia.
Tel: +6097676416, Fax: +6097676424,
Email: baharudin@usm.my, profbaha@gmail.com

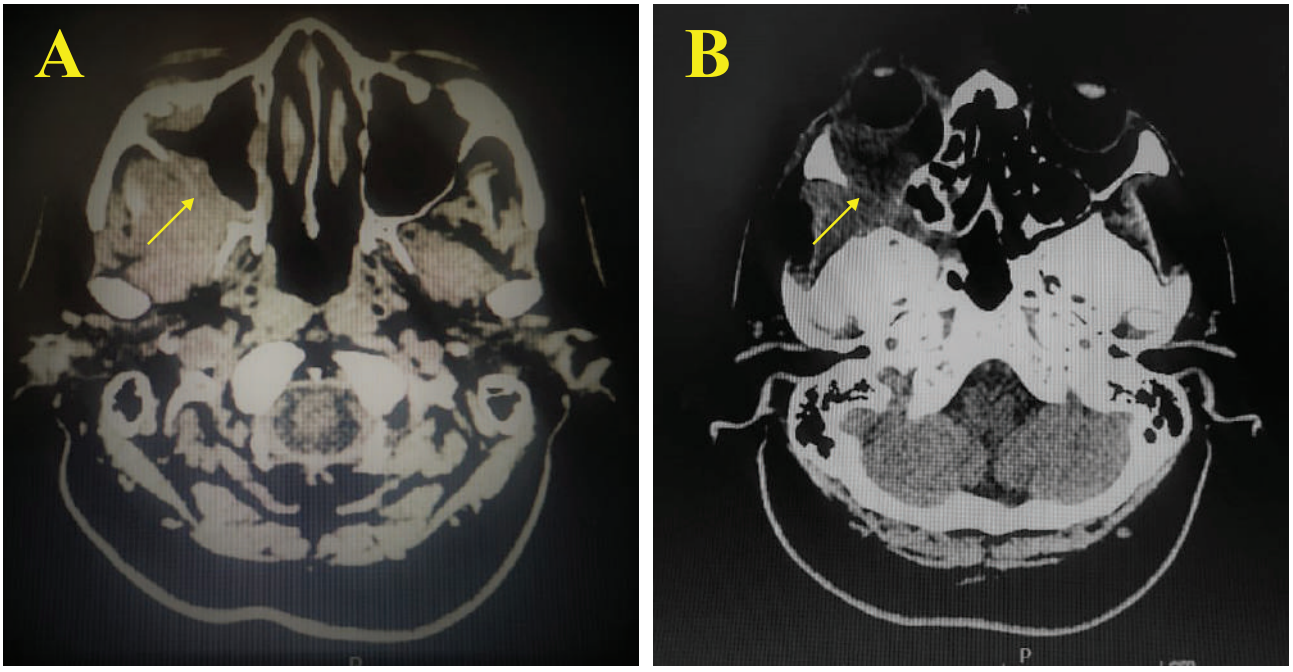

Figure 1: Computer Tomography(CT) scans of paranasal sinus (axial section) demonstrating heterogenous enhancing soft tissue mass (yellow arrow) at right infratemporal region extending into right maxillary sinus (A) and posterior part of the orbit (B).

The patient underwent transnasal endoscopic biopsy of the infratemporal mass(Fig. 2).

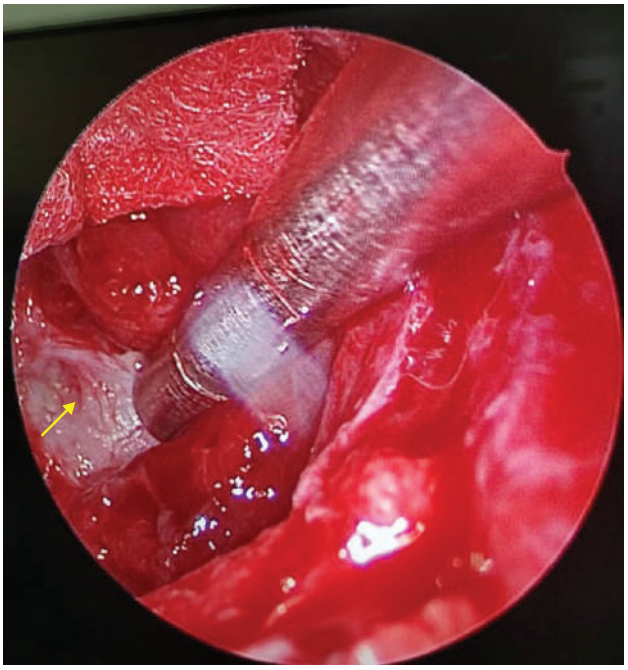

Figure 2: Nasal endoscopic view demonstrating whitish rubbery mass (yellow arrow) at posterior wall of right maxilla.

Intraoperative finding showed a whitish rubbery mass at the posterior–lateral wall of the right maxillary sinus. The mass was sent for histological examination, and it was reported as chronic inflammatory cells infiltration consists of neutrophils, lymphocytes and plasma cells. The patient was diagnosed with an inflammatory pseudotumor of right infratemporal fossa with orbital apex syndrome. The patient was treated with steroid 60 mg daily and tapering down for a total duration of two months. During the follow–up, we assessed the symptoms and clinical signs of the patient and performed an MRI to evaluate the responsiveness of the treatment. Magnetic Resonance Imaging (MRI) showed a reduction in the size of the lesion and improvement of clinical conditions (Fig 3). Currently, she is still under treatment for oral steroid and close follow up with our ORL clinic.

Discussion

Infratemporal fossa is the irregular retromaxillary space bounded superiorly by greater wing of the sphenoid, laterally by part of squamous of the temporal bone, medially by lateral surface of the lateral pterygoid plate and anteriorly by the infratemporal surface of the maxilla[4]. The incidence of inflammatory pseudotumor of the head and neck is approximately 15% of the overall cases of inflammatory pseudotumor throughout the body[1]. The regions of the head and neck that lesion commonly occurs is the orbit, maxillary sinus[5], the mandible[6], parapharyngeal space[7] and neck[8]. The lesion in the infratemporal area might be an independent growth from the infratemporal fossa itself, or direct extension of adjacent structure or metastasis from distant structures. The infratemporal region is a concealed area in which we are unable to assess by clinical or endoscopic examination. So any lesion or tumor in that area may grow unnoticed. The patients will only seek treatment when the lesion is considered large enough to cause compression effect to adjacent structure or developed secondary complications.

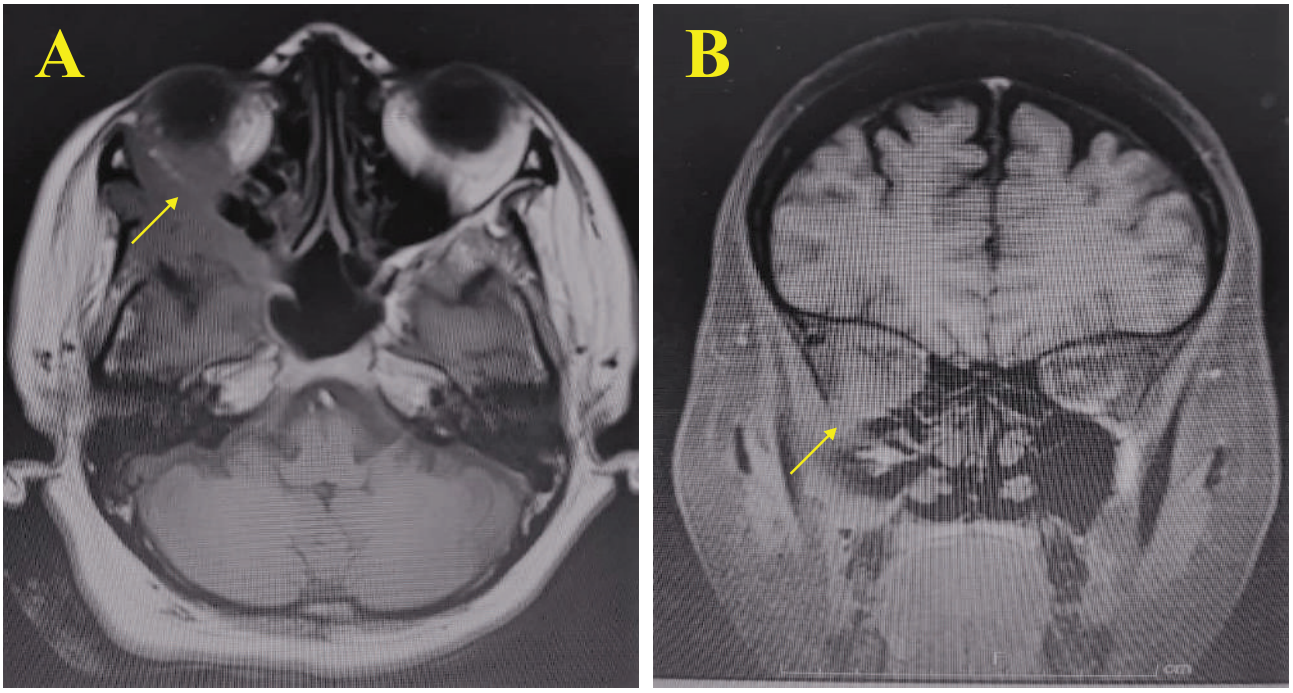

Figure 3: Magnetic Resonance Imaging (MRI) of paranasal sinus (T1) demonstrating slight reduction in the size of soft tissue mass (yellow arrow) at right infratemporal region, right maxillary sinus and right orbit after treatment with steroid (A– Axial section) (B–Coronal section)

In such cases, establishment of the diagnosis would be delayed and usually only noticed on radiological imaging. In our case, the patient developed orbital apex syndromes due to extension of the mass to the posterior part of the right orbit and caused a pressure effect to the cranial nerves that pass through the superior orbital fissure.

The role of the Computer Tomography scan (CT) is essential to assess the origin and extension of the lesion. Meanwhile, the Magnetic Resonance Imaging (MRI) can determine the intramuscular and intracranial infiltration[9]. Although the radiological imaging can provide information regarding the origin and extension of the lesion, they are unable to determine the histopathology of the lesion. In some cases, histologic diagnosis can be obtained by aspiration cytology; however, the biopsy is indicated if the cytology is inconclusive[9]. As the infratemporal fossa is anatomically concealed area, a few surgical approaches have been introduced to reach the lesions. Surgical approaches that introduce were transoral, transpalatal, transmandibular, transzygomatic, transcranial and transnasal endoscopic approach[10]. The common complications that may occur during the surgical intervention in the infratemporal fossa include temporomandibular joint dysfunction, facial nerve paresis, hearing impairment, cosmetic defect and vascular injuries[11]. For our patient, we performed a transnasal endoscopic approach to access the infratemporal fossa and obtain the biopsy. It is a minimally invasive, less bleeding and acceptable post–operative recovery[12]. No complications were observed post–procedure.

As for the treatment of inflammatory pseudotumor of the infratemporal fossa, several methods available including steroid therapy, radiotherapy and surgical resection. The previous study showed 80% of the patients with inflammatory pseudotumor have an excellent response to corticosteroid treatment; however, there is a 50% to 60% risk of disease relapse. It is recommended to continue the maintenance dose of corticosteroid for at least six months to prevent disease relapse[7]. The patients with poor response to systemic corticosteroids may have advantages from intralesional steroid treatments[13]. In general, there is no clear consensus regarding the starting dose of the steroid therapy and their maintenance dose; however, Lee et al. gradually reduce prednisolone from 60 mg daily[14].

There are reported cases of inflammatory pseudotumor of the skull base had a recurrence or resistant to steroid therapy despite the completed course of the steroid therapy. These groups of the patient require radiotherapy or surgical resection. Radiotherapy has shown effectiveness in patients with recurrence or poor response to steroids. Mendenhall et al. introduced a low dose of radiotherapy regime protocol to the patients with inflammatory pseudotumor of the eye socket (20–30 Gy at 2Gy per fraction). The local control rate after radiotherapy was 50% to 60% or higher; however, consensus regarding this protocol has yet to be reached[15]. Meanwhile, for surgical treatment, it is reserved for patients with poor response to steroid therapy and radiotherapy.

In our patient, we treated her with a high dose of steroid (60mg daily) and tapering down for a total duration of two months. Surgical treatment is not indicated for her due to extensive infiltration up to the cavernous sinus. In view of the need to take steroid therapy for prolonged period, preventive measures were taken to prevent adverse effects including tapering down the medications and prescribing proton pump inhibitor such as omeprazole to prevent peptic ulcer diseases. The prognosis for inflammatory pseudotumor is good, however, it still depends on lesion extension and treatment response.

Conclusions

Further studies need to be done on inflammatory pseudotumor of the infratemporal fossa in terms of case detection, surgical approaches and methods of treatment. Early case detection and prompt treatments are necessary to prevent complications of the diseases. Advances in radiotherapy as a treatment modality may provide a better outcome in the future.

Acknowledgement

None

Conflict of Interest

The authors declare no conflict of interest

Funding

None

References

1. Nishio N, Fujimoto Y, Nakashima T. Inflammatory pseudotumor of the infratemporal fossa leading to orbital apex syndrome. Journal of Craniofacial Surgery. 2014 Jul 1;25(4):1324–6.
2. Huang WH, Dai YC. Inflammatory pseudotumor of the nasal cavity. American journal of otolaryngology. 2006 Jul 1;27(4):275–7.
3. Rai A, Rajput R, Khatua RK, Singh M. Submasseteric abscess: A rare head and neck abscess. Indian Journal of Dental Research. 2011 Jan 1;22(1):166.
4. Tiwari R, Quak J, Egeler S, Smeele L, vd Waal I, vd Valk P, Leemans R. Tumors of the infratemporal fossa. Skull base surgery. 2000 Mar;10(01):0001–10.
5. Maruya SI, Kurotaki H, Hashimoto T, Ohta S, Shinkawa H, Yagihashi S. Inflammatory pseudotumour (plasma cell granuloma) arising in the maxillary sinus. Acta oto–laryngologica. 2005 Mar 1;125(3):322–7.
6. Gawande PD, Sambhus M, Garde JB, Halli R, Deshmukh V, Kulkarni A, Ashturkar A. Aggressive inflammatory pseudotumor of the mandible. Journal of Craniofacial Surgery. 2012 Jul 1;23(4):1101–3.
7. Maruya SI, Miura K, Tada YI, Masubuchi T, Nakamura N, Fushimi C, Sakashita T, Monma T, Kamata SE. Inflammatory pseudotumor of the parapharyngeal space: a case report. Auris Nasus Larynx. 2010 Jun 1;37(3):397–400.
8. Ceruse P, Ramade A, Vautrin R, Crozes C, Dubreuil C, Disant F. Inflammatory pseudotumor of the neck: a long–term result without surgical approach. Otolaryngology—Head and Neck Surgery. 2005 May;132(5):812–3.
9. Chong VF, Fan YF, Khoo JB, Lim TA. Comparing computed tomographic and magnetic resonance imaging visualisation of the pterygopalatine fossa in nasopharyngeal carcinoma. Annals of the Academy of Medicine, Singapore. 1995 May;24(3):436–41.
10. Wormald PJ, Robinson S. Transnasal endoscopic resection of benign tumors occurring from or extending into the infratemporal fossa. Operative Techniques in Otolaryngology–Head and Neck Surgery. 2006 Jun 1;17(2):97–101.
11. Casale J, Bordoni B. Anatomy, Head and Neck, Infratemporal Fossa. InStatPearls (Internet) 2020 Mar 10. StatPearls Publishing.
12. Robinson S, Patel N, Wormald PJ. Endoscopic management of benign tumors extending into the infratemporal fossa: A two-surgeon transnasal approach. The Laryngoscope. 2005 Oct;115(10):1818–22.
13. Patnana M, Sevrukov AB, Elsayes KM, Viswanathan C, Lubner M, Menias CO. Inflammatory pseudotumor: the great mimicker. American Journal of Roentgenology. 2012 Mar;198(3):W217–27.
14. Lee DK, Cho YS, Hong SH, Chung WH, Ahn YC. Inflammatory pseudotumor involving the skull base: response to steroid and radiation therapy. Otolaryngology—Head and Neck Surgery. 2006 Jul;135(1):144–8.
15. Mendenhall WM, Lessner AM. Orbital pseudotumor. American journal of clinical oncology. 2010 Jun 1;33(3):304–6.